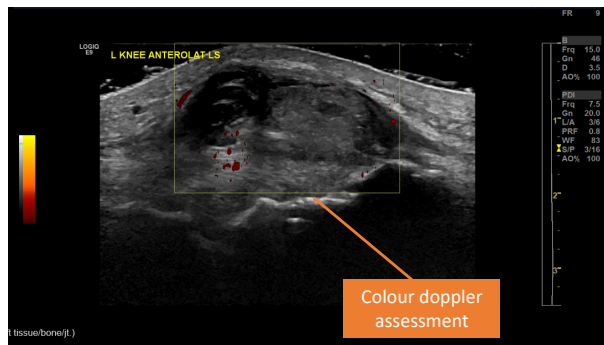
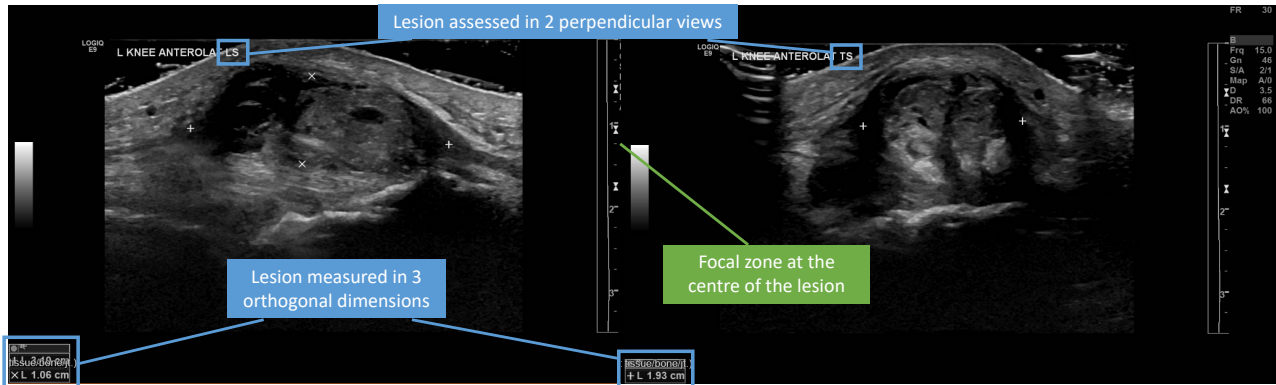


Musculoskeletal USG

Soft tissue mass assessment standard images



1. Lesion should be assessed in 2 perpendicular views with 3 orthogonal measurements.
2. Lesion should be assessed with colour doppler for any vascularity.
3. Focal zone should be placed at the centre of the lesion.