

# Clinical Radiology

## Major paediatric trauma radiology guidance

OCTOBER 2024



The Royal College of Radiologists



# Contents

<b>1</b>	<b>Key principles of the guidance .....</b>	<b>3</b>	
<b>2</b>	<b>Introduction .....</b>	<b>4</b>	
2.1	Who the guidance is for .....	4	
2.2	Scope and purpose of the guidance .....	4	
<b>3</b>	<b>Ionising radiation considerations .....</b>	<b>5</b>	
<b>4</b>	<b>Blunt trauma .....</b>	<b>6</b>	
4.1	Choice of imaging modality – general principles .....	6	
4.2	Imaging recommendations by anatomical area in blunt trauma .....	6	
	Head .....	6	
	Cervical spine .....	6	
	Thoracic and lumbar spine .....	7	
	Chest .....	7	
	Abdomen .....	7	
	Pelvis .....	8	
	Limbs .....	8	
4.3	Delayed presentation of injury .....	8	
4.4	Special considerations .....	8	
<b>5</b>	<b>Penetrating trauma – choice of imaging modality ..</b>	<b>9</b>	
5.1	Clinical assessment .....	9	
5.2	CT investigation .....	9	
5.3	Chest and extremity radiographs .....	9	
5.4	Hypovolemic patients .....	9	
5.5	CT coverage .....	9	
5.6	Bastion protocol .....	9	
5.7	Dual-phase imaging .....	10	
5.8	Wider CT coverage .....	10	
5.9	Primary report .....	10	
5.10	Wound sites .....	10	
<b>6</b>	<b>Blast injuries – choice of imaging modality .....</b>	<b>11</b>	
<b>7</b>	<b>Interventional radiology .....</b>	<b>12</b>	
	<b>References .....</b>	<b>13</b>	
	<b>Appendices</b>		
<b>A1</b>	<b>CT scan exclusion tool for blunt poly-trauma in under 16s .....</b>	<b>16</b>	
<b>A2</b>	<b>Camp Bastion contrast calculator and CT dose optimisation .....</b>	<b>17</b>	
	CT dose optimisation .....	18	
<b>A3</b>	<b>Suggested algorithm for the imaging of penetrating trauma in paediatric patients.....</b>	<b>19</b>	
<b>A4</b>	<b>Imaging algorithm for paediatric blast injuries ....</b>	<b>20</b>	
<b>A5</b>	<b>Acute primary assessment report for paediatric CT with major trauma .....</b>	<b>21</b>	
<b>A6</b>	<b>Background and supplementary information .....</b>	<b>22</b>	
	Paediatric major trauma CT scans – UK practice .....	22	
	Definition of penetrating trauma .....	22	
	Definition of blast injury .....	22	
	Classification of blast injury .....	23	
	<b>Acknowledgements .....</b>	<b>23</b>	

# 01

## Key principles of the guidance

1. Incidence of paediatric trauma is low compared with adults.
2. The growing child has different physiological and anatomical considerations, which require a different approach to imaging.
3. There is increased risk of ionising radiation in children. The ALARP (as low as reasonably practicable) principle should be adhered to.
4. Decision-making in imaging injured patients should always be underpinned by clinical discussions between senior level clinicians and radiologists.
5. Computed tomography (CT) is helpful in the paediatric trauma setting but is not mandatory and should be tailored to the patient.
6. The use of focused abdominal sonography in trauma (FAST) and unenhanced ultrasound are not appropriate and can provide false reassurance.
7. In penetrating trauma, contrast-enhanced imaging is the modality of choice.
8. Blast injuries demand adjustments to major trauma protocols. CT is the most effective imaging modality.

# 02

## Introduction

### 2.1 Who the guidance is for

This guidance is designed for treatment of paediatric patients presenting following major trauma. Separate adult-specific guidance can be found on the Royal College of Radiologists (RCR) website.<sup>1</sup> Where there is a perceived discrepancy, this paediatric document should take precedence for patients under 16 years of age. Each young person needs to be assessed clinically on a case-by-case basis.

### 2.2 Scope and purpose of the guidance

The guidance is intended to aid decision-making between clinicians and radiologists about the most appropriate imaging in paediatric major trauma including blunt trauma, penetrating trauma and blast injury.

There will always be situations in paediatric major trauma where the evidence base from research will be too sparse to fully inform all decisions. Consensus common sense and clinical experience will always have their place in making the right decision. Civility within teams making decisions should be encouraged. In an acute trauma resuscitation, the final decision on imaging should be that of the trauma team leader after taking input, when needed, from the wider team including radiology.

It is very hard to be prescriptive about all paediatric major trauma situations and what the necessary imaging requirements are. The recommendations in this guidance reflect consensus opinion based on available evidence and existing best practice. They are intended as a starting point to aid local decision-making based on what is known.

# 03

## Ionising radiation considerations

- 3.1 There is no safe lower level of radiation exposure.<sup>2,3,4,5</sup>
- 3.2 There is an increased risk from ionising radiation in children from factors such as cumulative radiation risk over a lifetime, longer lifetime to express relative risk and a growing child has more radiosensitive tissues.<sup>6,7,8,9,10</sup>
- 3.3 The ALARP principle should be adhered to.
- 3.4 Using the ALARP principle in a trauma setting, the initial clinical question needs to be: 'Does this child need imaging at all?'
- 3.5 If imaging is required, further questions should be asked about which anatomical areas need to be covered, and whether primary imaging should be plain radiographs or an alternative modality such as CT.

# 04

## Blunt trauma

See [Appendix 1](#): CT scan exclusion tool for blunt poly-trauma in under 16s.

### 4.1 Choice of imaging modality: general principles

- 4.1.1 The modality, extent and timing of imaging is not mandatory. Therefore, following an appropriate senior level of discussion between the referring physician and the radiologist, imaging should be tailored to the patient.
- 4.1.2 Contrast-enhanced CT can be helpful in the paediatric trauma setting but should be applied judiciously.<sup>11,12,13</sup>
- 4.1.3 FAST and unenhanced ultrasound may not be suitable for assessing blunt abdominal trauma and could provide false reassurance.<sup>14,15</sup>
- 4.1.4 Contrast-enhanced ultrasound could be considered appropriate in cases once discussed with an expert.<sup>16,17,18</sup>
- 4.1.5 Magnetic resonance imaging (MRI) is primarily reserved for potential spinal cord injury, although access may be difficult.
- 4.1.6 A normal radiograph for specific areas can help to tailor management.
- 4.1.7 All imaging pathways for suspected injury must begin with clinical history, examination and observation as well as considering the patient's likely onward journey.
- 4.1.8 If CT is deemed the most appropriate investigation, suitable dose reduction procedures should be used, including advanced iterative reconstruction software applications, balancing the time delay in producing the definitive image with the current clinical situation.
- 4.1.9 Significant dose reduction can be achieved in paediatric patients without any loss of diagnostic information through the use of judicious kilovolt and milliamperage reduction.<sup>19</sup>

### 4.2 Imaging recommendations by anatomical area in blunt trauma

#### Head

- 4.2.1 It is recommended to follow the imaging algorithm for selecting people under 16 for a CT head scan (see algorithm 2) in the NICE guidance *Head injury: assessment and early management*.<sup>20</sup>
- 4.2.2 3D CT reconstruction of the skull vault has the capability of increasing sensitivity for the detection of linear fractures and is highly recommended.<sup>21</sup>

#### Cervical spine

- 4.2.3 It is recommended to follow the imaging algorithm for selecting people under 16 for a cervical spine scan (algorithm 4) in the NICE guidance *Head injury: assessment and early management*.<sup>20</sup>

# 04

## Blunt trauma

### Thoracic and lumbar spine<sup>22,23</sup>

- 4.2.4 Potential spinal injuries should be assessed on a case-by-case basis with appropriate imaging guided by discussion with the radiologist where clinical condition allows.
- 4.2.5 Clinical assessment should underpin investigations.
- 4.2.6 Plain radiographs of the injured region will generally be the primary investigation.
- 4.2.7 Targeted CT of an area may be required for further assessment.
- 4.2.8 CT of the lumbar spine is included in CT of the abdomen and pelvis.
- 4.2.9 Where there are definitive neurological signs, the primary imaging modality should be MRI where possible.

### Chest

- 4.2.10 The primary investigation for blunt chest trauma is the chest X-ray. This will detect significant pneumothorax, haemothorax, displaced rib fractures, gross mediastinal abnormalities and gross diaphragmatic injuries.<sup>24,25,26</sup>
- 4.2.11 Further imaging in blunt chest trauma should be dictated by the nature of the trauma, the clinical condition of the child and the initial radiographic findings.
- 4.2.12 Penetrating trauma is an indication for contrast-enhanced chest CT due to the incidence of occult vascular injury.
- 4.2.13 Contrast-enhanced CT should also be considered in cases where there has been a rapid deceleration (defined as fall >6 metres) or high-impact motor vehicle crash (>40 miles/hour), intoxication, reduced Glasgow Coma Scale (GCS) or distracting painful injury.<sup>27</sup>
- 4.2.14 CT can be omitted in patients with normal chest film and clinical examination as it is unlikely to lead to a change in management.<sup>28</sup>

### Abdomen

- 4.2.15 Where clinically indicated, contrast-enhanced CT of the abdomen and pelvis is the modality of choice for the assessment of acute traumatic intra-abdominal injury.<sup>29,30,31,32</sup>
- 4.2.16 Single-volume dual-contrast CT is advised to minimise radiation burden.
- 4.2.17 An example of a suitable contrast and timings calculator is included (see the Camp Bastion contrast wheel, [Appendix 2](#)).
- 4.2.18 A hand injection of contrast is appropriate in very small children and babies.
- 4.2.19 Decisions to perform abdominopelvic CT should be made on the basis of the clinical history and examination.<sup>33</sup>
- 4.2.20 Where there is an isolated head injury, a reduced GCS score should not be the only justification for abdominal CT. The decision to perform abdominal CT should be made on the basis of the clinical history and examination. The following clinical variables have been found to be associated with intra-abdominal injury and may indicate the need for abdominopelvic CT.<sup>34,35</sup>
  - Lap belt or handlebar injuries
  - Abdominal wall ecchymosis
  - Abdominal tenderness in a conscious patient
  - Abdominal distension
  - Clinical evidence of persistent hypovolaemia; for example, persistent unexplained tachycardia
  - Blood from the urethra, rectum or nasogastric tube.

# 04

## Blunt trauma

- 4.2.21 Abdominal injuries are rare where there is neurological impairment in the absence of abdominal signs and symptoms.<sup>36</sup>
- 4.2.22 Abdominopelvic CT findings have been documented to influence patient monitoring and management plans.<sup>37</sup>
- 4.2.23 A normal CT strongly predicts the lack of subsequent deterioration of a patient's condition.<sup>37</sup>

### Pelvis

- 4.2.24 Pelvic fractures are rare in children.
- 4.2.25 A screening pelvic radiograph is not indicated in all cases.<sup>38,39,40,41</sup>
- 4.2.26 Pelvic imaging should only be considered if there are concerns after clinical assessment.
- 4.2.27 The presence of a pelvic binder is not an indication in isolation for imaging without prior clinical assessment.
- 4.2.28 Pelvic fractures can be associated with multi-organ injuries. The bony pelvis will be included on CT evaluation of the abdomen and pelvis. Where clinically indicated, contrast-enhanced CT of the abdomen and pelvis is the modality of choice.
- 4.2.29 When there are high clinical concerns or radiologically proven pelvic fractures, imaging post removal of the pelvic binder is sometimes required. When this is the case both the orthopaedic team and wider team should be in attendance when the binder is removed in case the patient deteriorates.

### Limbs

- 4.2.30 Using the clinical history and examination, clinicians should request plain radiographs of the injured region as the primary investigation.
- 4.2.31 This will usually be anteroposterior and lateral views including the adjacent joints.
- 4.2.32 CT may be required for complex fractures or concern of vascular injury.

## 4.3 Delayed presentation of injury

- 4.3.1 Imaging evaluation in delayed presentations of blunt trauma is difficult given the heterogeneity of the aetiology and subsequent clinical presentation.
- 4.3.2 Consideration should be given to contrast-enhanced imaging, given the limitations in non-enhanced imaging, although the initial aetiology and clinical evolution of the patient remain important factors in determining onward imaging.

## 4.4 Special considerations

- 4.4.1 The use of radiological imaging to exclude injury should be considered in situations where history or clinical examination is compromised.
- 4.4.2 This includes the following:
  - Children with decreased level of consciousness including intubated patients
  - Unwitnessed injury in the non-verbal child
  - Children in situations with limited clinical observation such as awaiting hospital transfer or needing immediate operative intervention
  - Clinical concerns regarding suspected physical abuse (SPA), which is a major cause of trauma in infants; radiological investigation of SPA should follow the RCR guidance The radiological investigation of suspected physical abuse in children.<sup>42</sup>



# 05

## Penetrating trauma – choice of imaging modality

See [Appendix 3](#): Suggested imaging algorithm for penetrating trauma in paediatric patients

In the event of penetrating trauma, while post-contrast CT imaging is the modality of choice for patients, it is important to consider several factors, including the following.<sup>43</sup>

### 5.1 Clinical assessment

Clinical assessment (for example, entry site wounds) may underestimate the extent, depth and number of penetrating injuries. Therefore, the choice of imaging should account for this potential uncertainty.

### 5.2 CT investigation

CT coverage and the timing of the contrast injection should be specific to each case. Therefore, senior-level discussion between the emergency physician and radiologist should precede any CT investigation, highlighting clinical concerns, potential underlying injuries that need to be excluded and urgency of the scan.

### 5.3 Chest and extremity radiographs

Both these radiographs are complementary investigations and have a role in the acute patient presentation.

- Chest radiographs can identify foreign bodies and pathologies; for example, pneumo/haemothorax that would require immediate treatment.
- Extremity radiographs are valuable in excluding concomitant fractures and residual foreign bodies.

### 5.4 Hypovolemic patients

Clinical assessment of the number, size and depth of any puncture wound in hypovolemic patients is difficult to assess, and it is safer to assume the patient has suffered a greater level of trauma rather than take a more conservative approach.

### 5.5 CT coverage

If the trauma is consequent to crime-related assault, the patient may be less forthcoming with a true reflective history. When deciding on the extent of CT coverage, ask 'Is there any part of the body that we do not need to image?'

### 5.6 Bastion protocol

In the majority of cases, the timing for the contrast-enhanced CT should follow the Bastion protocol (see [Appendix 2](#)).

# 05

## Penetrating trauma

### 5.7 Dual-phase imaging

In the case of extremity injuries or suspected central aortic injuries, imaging may need to be modified to obtain a more definitive arterial phase. If there are concerns about ongoing haemorrhage or an intra-abdominal injury, dual-phase imaging may be required. However, it is important to bear in mind that dual-phase imaging may provide falsely reassuring results due to enhanced vasoconstriction response in the paediatric population.

### 5.8 Wider CT coverage

When a puncture occurs at the junction of two body parts (for example, the base of the neck/upper third of the chest or lower chest/upper abdomen), wider CT coverage is indicated. In these situations, imaging of the neck and chest, or chest and abdomen, in the respective scenarios, would be recommended as transdiaphragmatic blade injuries cannot be excluded.

### 5.9 Primary report

The primary report should correlate soft-tissue lesions with available clinical information. Imaging may reveal clinically occult wound sites and map the wound trajectory.

### 5.10 Wound sites

For each wound site, an assessment of its location, depth and associated visceral injuries should be documented. For ballistic injuries, it is important to evaluate the bullet track and location of metallic fragments.

# 06

## Blast injuries – choice of imaging modality

See [Appendix 4](#): Imaging algorithm for paediatric blast injuries

This algorithm aims to provide quick and essential information for managing several paediatric victims with multiple known and occult injuries who present in a short period of time to the hospital.

Imaging modalities such as X-ray and CT suggested in the algorithm are prioritised on resources and apply to the first wave of victims, as well as the following ones typically 8 and 16 hours after the event.<sup>44</sup>

- 6.1 Adjust major trauma protocols to balance the need for vital information with the CT radiation burden for effective imaging modality.<sup>45,46</sup>
- 6.2 Planning the first hours of blast injury events is crucial to assure good patient flow through regular major incident exercises. However, predicting the needs for the days and weeks to follow is equally important.
- 6.3 Ensure rapid and unidirectional patient flow from the emergency department to theatres, intensive care units and wards.
- 6.4 All victims will need some form of imaging to direct subsequent management (for example, exploration of injuries and removal of shrapnel in theatre, admission to intensive care and admission to wards).
- 6.5 Avoid MRI for acute investigation of blast injuries due to the risk associated with likely ferromagnetic properties of shrapnel.

---

# 07

## Interventional radiology

---

- 7.1 Patients who require interventional radiology input should initially be discussed with the receiving hospital's interventional radiology team, who may have appropriate skills and anaesthetic, intensive care and paediatric surgical support to treat locally. If the patient cannot be managed by interventional radiology at the receiving hospital, they should be transferred to an appropriate major trauma centre.
- 7.2 Please refer to the RCR report Improving paediatric interventional radiology services in the UK.<sup>44</sup>

# 08

## References

- 1 The Royal College of Radiologists. *Major adult trauma radiology guidance*. London: The Royal College of Radiologists, 2024.
- 2 Brenner D, Elliston C, Hall E, Berdon W. Estimated risks of radiation-induced fatal cancer from pediatric CT. *AJR Am J Roentgenol* 2001; **176**(2): 289–296.
- 3 Pearce MS, Salotti JA, Little MP *et al*. Radiation exposure from CT scans in childhood and subsequent risk of leukaemia and brain tumours: a retrospective cohort study. *Lancet* 2012; **380**(9840): 499–505.
- 4 Einstein AJ. Beyond the bombs: cancer risks of low-dose medical radiation. *Lancet* 2012; **380**: 455–457.
- 5 Matthews J, Forsythe A, Brady Z *et al*. Cancer risk in 680 000 people exposed to CT scans in childhood or adolescence: data linkage of 11 million Australians. *BMJ* 2013; **346**: f2360.
- 6 Arthurs OJ, Bjørkum AA. Safety in pediatric imaging: an update. *Acta Radiol* 2013; **54**(9): 983–990.
- 7 Kossi DA, Rage E, Leuraud K *et al*. Early life ionizing radiation exposure and cancer risks: systematic review and meta-analysis. *Pediatric Radiology* 2023; **51**: 45–56.
- 8 Hong JY, Han K, Jung JH *et al*. Association of exposure to diagnostic low-dose ionizing radiation with risk of cancer among youths in South Korea. *JAMA Netw Open* 2019 Sep 4; **2**(9): e1910584.
- 9 Hauptmann M, Byrnes G, Cardis E *et al*. Brain cancer after radiation exposure from CT examinations of children and young adults: results from the EPI-CT cohort study. *Lancet Oncol* 2023 Jan; **24**(1): 45–53 2022. [https://doi.org/10.1016/S1470-2045\(22\)00655-6](https://doi.org/10.1016/S1470-2045(22)00655-6).
- 10 Miglioretti DL, Johnson E, Williams A *et al*. The use of computed tomography in pediatrics and the associated radiation exposure and estimated cancer risk. *JAMA Pediatr* 2013; **167**(8): 700–707.
- 11 Frellesen C, Klein D, Tischendorf P *et al*. Indication of whole body computed tomography in pediatric polytrauma patient. *Eur J Radiol* 2018 Aug; **105**: 32–40. doi: 10.1016/j.ejrad.2018.05.022. Epub 2018 May 25.
- 12 Nellensteijn DR, Greuter MJ, El Mounni M *et al*. The use of CT scan in hemodynamically stable children with blunt abdominal trauma: look before you leap. *Eur J Pediatr Surg* 2016; **26**: 332–335.
- 13 Braungart S, Beattie T, Midgley P, Powis M. Implications of a negative abdominal CT in the management of pediatric blunt abdominal trauma. *J Pediatr Surg* 2017; **52**(2): 293–298.
- 14 Quan GE, Kendall JL, Bogseth MC *et al*. Predictors of false-negative focused assessment with sonography for trauma examination in pediatric blunt abdominal trauma. *Pediatr Emerg Care* 2020; **36**(5): e274–e279. doi: 10.1097/PEC.0000000000002094.
- 15 Liang T, Roseman E, Gao M, Sinert R. The utility of the focused assessment with sonography in trauma examination in pediatric blunt abdominal trauma: a systematic review and meta-analysis. *Pediatr Emerg Care* 2021; **37**(2): 108–118. doi: 10.1097/PEC.0000000000001755.

# 08

## References

- 16 Sidhu PS, Cantisani V, Dietrich CF *et al.* The EFSUMB guidelines and recommendations for the clinical practice of contrast-enhanced ultrasound (CEUS) in non-hepatic applications: update 2017 (long version). *Ultraschall Med* 2018 Apr; **39**(2): e2-e44. doi: 10.1055/a-0586-1107. Epub 2018 Mar 6. PMID: 29510439.
- 17 Paltiel HJ, Barth RA, Bruno C *et al.* Contrast-enhanced ultrasound of blunt abdominal trauma in children. *Pediatr Radiol* 2021 Nov; **51**(12): 2253–2269. doi: 10.1007/s00247-020-04869-w. Epub 2021 May 12. PMID: 33978795.
- 18 Trinci M, Piccolo CL, Ferrari R, Galluzzo M, Ianniello S, Miele V. Contrast-enhanced ultrasound (CEUS) in pediatric blunt abdominal trauma. *J Ultrasound* 2019 Mar; **22**(1): 27–40. doi: 10.1007/s40477-018-0346-x. Epub 2018 Dec 8. PMID: 30536214; PMCID: PMC6430291.
- 19 Gottumukkala RV, Kalra MK, Tabari A, Otrakji A, Gee MS. Advanced CT techniques for decreasing radiation dose, reducing sedation requirements, and optimizing image quality in children. *Radiographics* 2019 May–Jun; **39**(3): 709–726. doi: 10.1148/rg.2019180082. Epub 2019 Mar 29. PMID: 30924753.
- 20 National Institute for Health and Care Excellence (NICE). Head injury: assessment and early management. NICE guideline [NG232], May 2023. [www.nice.org.uk/guidance/ng232](http://www.nice.org.uk/guidance/ng232) and [www.nice.org.uk/guidance/ng232/resources/imaging-algorithm-pdf-13061125549](http://www.nice.org.uk/guidance/ng232/resources/imaging-algorithm-pdf-13061125549) (last accessed 12 August 2024).
- 21 Orman G, Wagner MW, Seeburg D *et al.* Pediatric skull fracture diagnosis: should 3D CT reconstructions be added as routine imaging? *J Neurosurg Pediatr* 2015 Oct; **16**(4): 426–31. doi: 10.3171/2015.3.PEDS1553. Epub 2015 Jul 17. PMID: 26186360.
- 22 Derderian SC, Greenan K, Mirsky DM *et al.* The utility of magnetic resonance imaging in pediatric trauma patients suspected of having cervical spine injuries. *J Trauma Acute Care Surg* 2019 Dec; **87**(6): 1328–1335. doi: 10.1097/TA.0000000000002487. PMID: 31764482.
- 23 Mistry D, Munjal H, Ellika S, Chaturvedi A. Pediatric spine trauma: a comprehensive review. *Clin Imaging* 2022; **87**: 61–76. doi: 10.1016/j.clinimag.2022.04.012. Epub 2022 Apr 28. PMID: 35534318.
- 24 Holl EM, Marek AP, Nygaard RM, Richardson CJ, Hess DJ. Use of chest computed tomography for blunt pediatric chest trauma. *Pediatr Emerg Care* **36**(2): 81–86. doi: 10.1097/PEC.0000000000002040. PMID: 31904738..
- 25 Holscher CM, Faulk LW, Moore EE. Chest computed tomography imaging for blunt pediatric trauma: not worth the radiation risk. *J Surg Res* 2013 Sep; **184**(1): 352–357. doi: 10.1016/j.jss.2013.04.044. Epub 2013 May 24. PMID: 23746760.
- 26 Golden J, Isani M, Bowling J. Limited chest computed tomography in the evaluation of pediatric thoracic trauma. *J Trauma Acute Care Surg* 2016; **81**: 271–277. doi: 10.1097/TA.0000000000001110. PMID: 27192472.
- 27 Knipe H. NEXUS chest. Radiopaedia.org, 14 July 2017. <https://doi.org/10.53347/rID-54301> (last accessed 10 Jul 2023).
- 28 Patel RP, Hernanz-Schulman M, Hilmes MA, Yu C, Ray J, Kan JH. Pediatric chest CT after trauma: impact on surgical and clinical management. *Pediatr Radiol* 2010; **40**(7): 1246–1253.

# 08

## References

- 29 Moore HB, Faulk LW, Moore EE *et al.* Mechanism of injury alone is not justified as the sole indication for computed tomographic imaging in blunt pediatric trauma. *J Trauma Acute Care Surg* 2013; **75**(6): 995–1001.
- 30 Orwig D, DeCou J. Towards evidence-based emergency medicine: best BETs from the Manchester Royal Infirmary. BET 4: is physical exam and laboratory data sufficient to exclude intra-abdominal injury in the paediatric trauma patient? *Emerg Med J* 2012; **29**(3): 258–260.
- 31 Eppich WJ, Zonfrillo MR. Emergency department evaluation and management of blunt abdominal trauma in children. *Curr Opin Pediatr* 2007; **19**(3): 265–269.
- 32 Taylor GA. Imaging of pediatric blunt abdominal trauma: what have we learned in the past decade? *Radiology* 1995; **195**(3): 600–601.
- 33 Neish AS, Taylor GA, Lund DP, Atkinson CC. Effect of CT information on the diagnosis and management of acute abdominal injury in children. *Radiology* 1998; **206**(2): 327–331.
- 34 Sivit CJ. Abdominal trauma imaging: imaging choices and appropriateness. *Pediatr Radiol* 2009; **39**(Suppl 2): S158–S160.
- 35 Sivit CJ. Imaging children with abdominal trauma. *AJR Am J Roentgenol* 2009; **192**(5): 1179–1189.
- 36 Holmes JF, Sokolove PE, Brant WE *et al.* Identification of children with intra-abdominal injuries after blunt trauma. *Ann Emerg Med* 2002; **39**(5): 500–509.
- 37 Avarello JT, Cantor RM. Pediatric major trauma: an approach to evaluation and management. *Emerg Med Clin North Am* 2007; **25**(3): 803–836, x
- 38 Rees MJ, Aickin R, Kolbe A, Teele RL. The screening pelvic radiograph in pediatric trauma. *Pediatr Radiol* 2001; **31**(7): 497–500.
- 39 Lagisetty J, Slovis T, Thomas R, Knazik S, Stankovic C. Are routine pelvic radiographs in major pediatric blunt trauma necessary? *Pediatr Radiol* 2012; **42**(7): 853–858.
- 40 Leonard M, Ibrahim M, McKenna P, Boran S, McCormack D. Paediatric pelvic ring fractures and associated injuries. *Injury* 2011; **42**(10): 1027–1030.
- 41 Haasz M, Simone LA, Wales PW *et al.* Which pediatric blunt trauma patients do not require pelvic imaging? *J Trauma Acute Care Surg* 2015; **79**: 828Y832.
- 42 The Royal College of Radiologists. *The radiological investigation of suspected physical abuse in children*. London: The Royal College of Radiologists, 2019.
- 43 Low SBL, Tan Y, Patel H, Johnson K. Four-year experience of penetrating injuries: findings from a major paediatric trauma centre in the UK. *Clin Radiol* 2022 Apr; **77**(4): 244–254. doi: 10.1016/j.crad.2022.01.037. Epub 2022 Feb 12. PMID: 35168758.
- 44 The Royal College of Radiologists. *Improving paediatric interventional radiology services in the UK*. London: The Royal College of Radiologists, 2023. [www.rcr.ac.uk/press-and-policy/policy-priorities/improving-paediatric-interventional-radiology-services-uk](http://www.rcr.ac.uk/press-and-policy/policy-priorities/improving-paediatric-interventional-radiology-services-uk).
- 45 The Royal College of Radiologists. *Paediatric major trauma protocols*. London: The Royal College of Radiologists, 2014.
- 46 Pollard C, Irwin G, Spiers M. Imaging flowchart for major paediatric trauma. RHC Glasgow, April 2019.

# A1

## CT scan exclusion tool for blunt poly-trauma in under 16s

This tool is aimed to help with a focused CT scan approach in children rather than undertaking whole-body CT scans without consideration. **This tool should be used in conjunction with RCR guidance.**

- If an anatomical region satisfies all the criteria, not scanning that anatomical region should be considered.
- Senior clinical discretion is still advised.

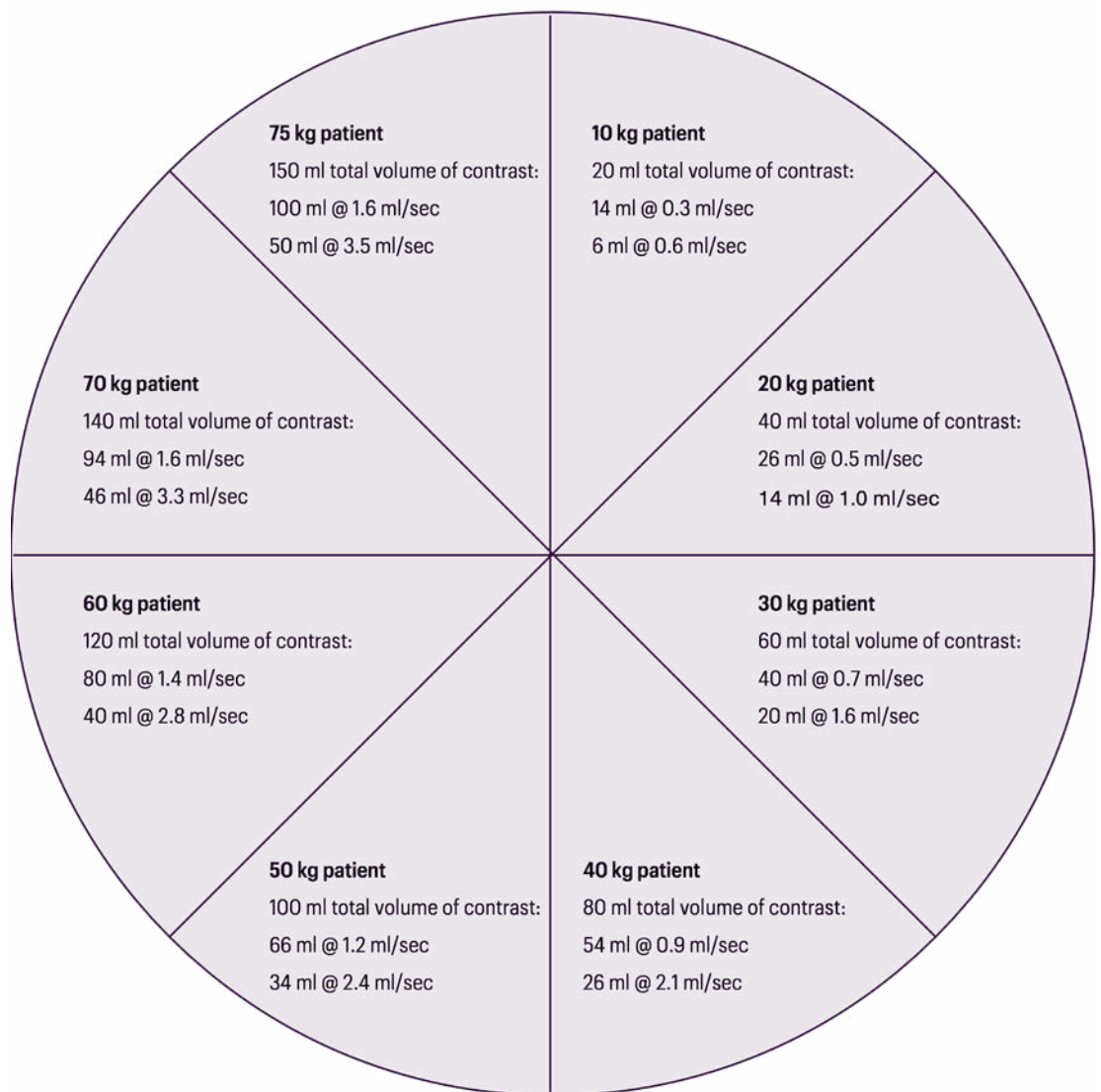
Anatomical region	
<b>1. Head</b>	
a. Not reduced GCS below 13 or intubated	
b. Did not trigger NICE guidelines	
<b>2. Neck</b>	
a. Not reduced GCS below 13 or intubated	
b. Did not trigger NICE guidelines	
<b>3. Chest</b>	
a. Chest X-ray normal	
b. Chest exam normal	
c. Not rapid deceleration (Defined as fall >6 metres or high-impact motor vehicle crash >40 mph)	
<b>4. Abdomen</b>	
a. Not lap belt or handlebar injuries	
b. No abdominal wall ecchymosis	
c. No abdominal tenderness in a conscious patient	
d. No abdominal distension	
e. No clinical evidence of persistent hypovolaemia; eg persistent unexplained tachycardia	
f. No blood from the rectum or nasogastric tube	
<b>5. Spine</b>	
a. No midline tenderness	
b. Low level of concern on mechanism	
c. No neurology	
(MRI should be used where possible as first line)	
<b>6. Limbs</b>	
a. No complex fractures (consider)	
b. No concern of vascular injuries (consider)	
<b>Wider concerns, which could lower the threshold to CT scan:</b>	
a. Patient needs emergency operation	
b. Patient has long secondary transfer	
c. Patient will be sedated in critical care area for an extended period	



# A2

## Camp Bastion contrast calculator and CT dose optimisation

Scan protocol: 2/3 contrast volume injected at slow rate x, and 1/3 volume injected at approximately 2x. Contrast rates are calculated for injection phase to last 70 secs. Scan initiated at 70 seconds.



# A2

## Contrast calculator

## CT dose optimisation

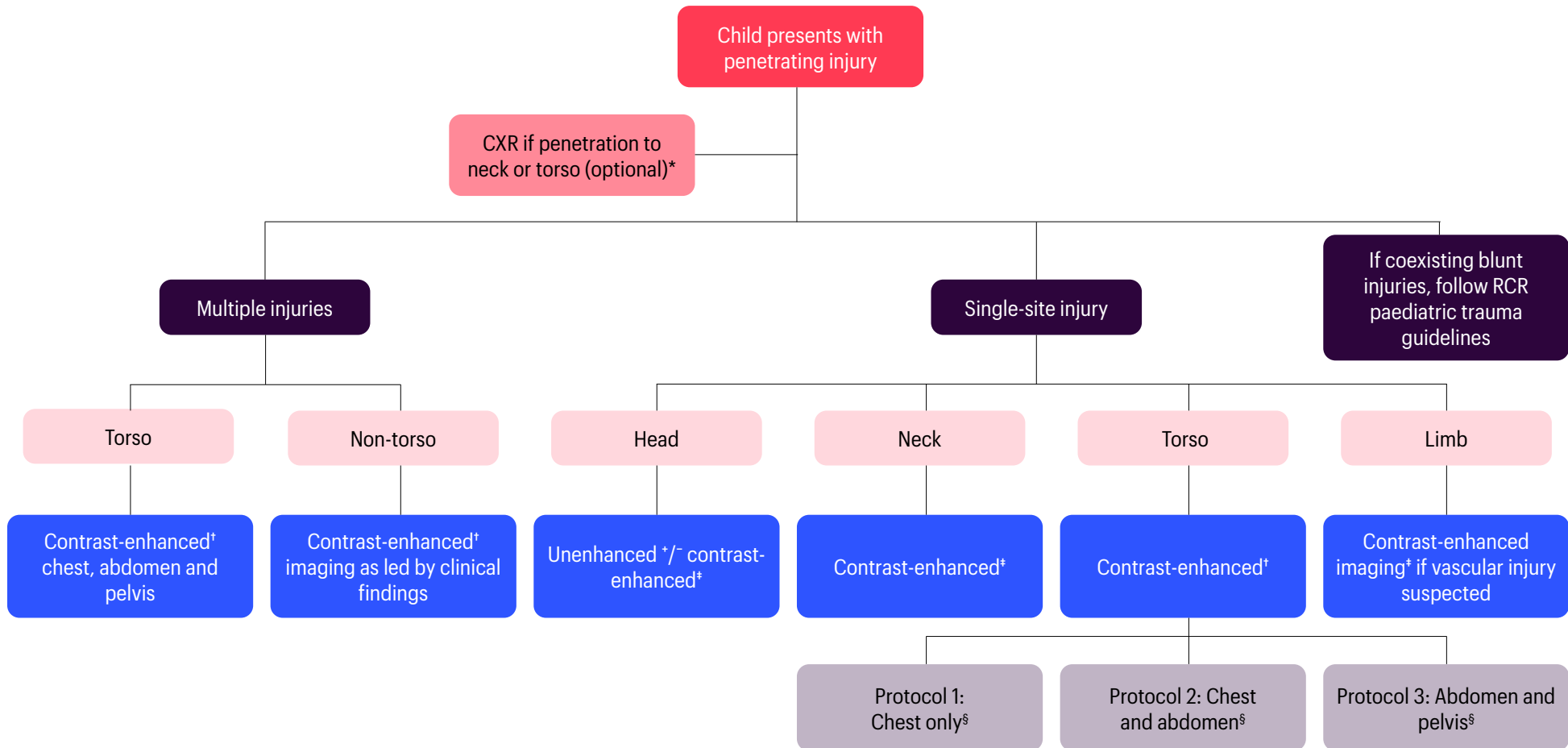
1. Use scan parameters – mA, kVp and pitch according to a patient's weight or age.<sup>a</sup> For example:  
10 kg patient. 20 ml total volume of contrast. 6 ml at 0.5 ml/sec then 14 ml at 1 ml/sec. Scan initiated at 70 secs.
2. There should be an acceptable level of noise for 'trauma scanning'.
3. Single-phase acquisition with a dual-contrast model.
4. Use iterative reconstruction, tube current modulation or organ-based modulation where available.<sup>b</sup>
5. Use protocols to reduce dose to particularly radiosensitive areas (for example, lens) where possible.

### References

- a. Brady Z, Ramanauskas F, Cain TM, Johnston PN. Assessment of paediatric CT dose indicators for the purpose of optimisation. *Br J Radiol* 2012; **85**(1019): 1488–1498.
- b. Brady SL, Moore BM, Yee BS, Kaufman RA. Pediatric CT: implementation of ASIR for substantial radiation dose reduction while maintaining pre-ASIR image noise. *Radiology* 2014; **270**(1): 223–231.

## A3

# Suggested algorithm for the imaging of penetrating trauma in paediatric patients



\* The need for CXR is a clinician-led decision, based on factors such as history and examination findings, patient stability, need for intervention, availability of cross-sectional imaging, etc

† Bastion or modified Bastion protocol is considered the standard for contrast administration, although the choice between the two protocols would be based on local practice

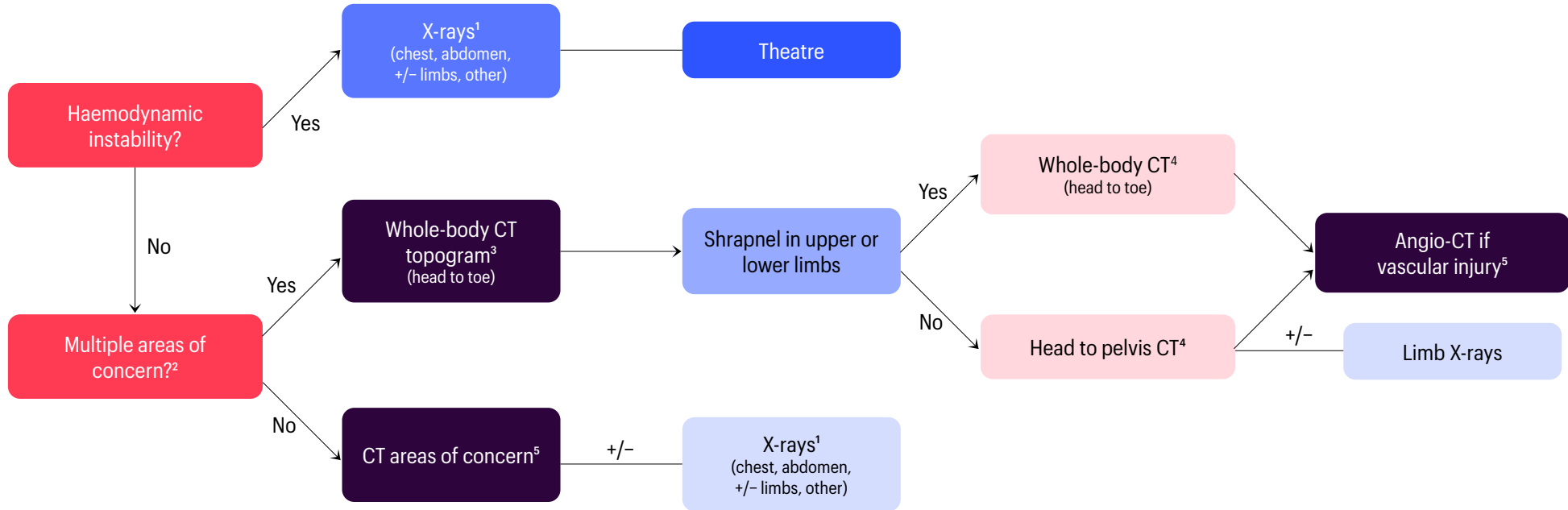
‡ Consider CT angiogram in place of Bastion or modified Bastion protocol if arterial injury is suspected

§ A wider CT coverage rather than a single body part should be considered if the entry wound occurs at the junction of two body parts or if there was a possibility of a wound depth or trajectory crossing between two body parts

Source: Low SBL, Tan Y, Patel H, Johnson K. Four-year experience of paediatric penetrating injuries: findings from a paediatric major trauma centre in the UK. *Clin Radiol* 2022; **77**: 244–254.

## A4

## Imaging algorithm for paediatric blast injuries



1. Include areas where there are visible injuries (eg point of entry for possible shrapnel) to guide surgical exploration
2. Low threshold for wider CT coverage when injuries suspected in multiple regions (eg head, neck, abdomen and pelvis, bones, vascular injuries)
3. Provides a whole-body map of shrapnel location and distribution
4. Non-contrast for head, split bolus for chest, abdomen, pelvis and limbs
5. Used to plan management by interventional radiology

# A5

## Acute primary assessment report for paediatric CT with major trauma

Patient name		Patient number		Date of scan	
--------------	--	----------------	--	--------------	--

To guide initial management only. A formal report will follow. The trauma team will be notified of any major alterations to this primary assessment.

### Primary assessment trauma plain films (for stable children)

Cervical spine	
Normal	No CT C-spine indicated
Abnormal/clinical suspicion	CT C-spine required
Chest X-ray	
Normal	No CT chest indicated Proceed to CT abdomen/pelvis if needed
Abnormal/clinical suspicion	CT chest abdomen/pelvis required

### CT scanning preliminary review

Airway			
ET placement	N/A	Satisfactory	Unsatisfactory
Airway obstruction		Yes	No
Breathing			
Contusion		Yes	No
Laceration		Yes	No
Pneumothorax		Yes	No
Haemothorax/pleural effusion		Yes	No
Chest drain placement	N/A	Satisfactory	Unsatisfactory
Circulation (bleeding)			
Pericardial effusion		Yes	No
Thoracic injury		Yes	No
Abdominal injury	Retroperitoneal	Yes	No
	Visceral	Yes	No
Pelvic injury		Yes	No
Soft tissue		Yes	No
Disability			
Intracranial bleed/oedema		Yes	No
Major spinal injury (cord compromise)		Yes	No

Comments	
Name of radiologist	
Time	

# A6

## Background and supplementary information

### Paediatric major trauma CT scans – UK practice

- Data from the Trauma Audit Research Network (TARN) show that major trauma centres that see a large or high number of children have a reduced percentage of whole-body CT scans compared with the national average.<sup>a</sup> This appears to be achieved without an increase in adverse final outcome for the patients.
- The causes of the different CT scan rates between hospitals are multifactorial, including the following.
  - Experience in seeing and assessing children with major trauma.
  - Assessment of the need for and safety of transfer to the nearest children's major trauma centre as well as the speed of local CT scan procedures.
  - Some trauma networks in selected cases will image after secondary transfer.
  - Having rapid access to diagnostics and definitive care for children is likely to make it safer to observe children in hospitals with less imaging. This is likely making it easier for clinicians in more child-focused hospitals to be more judicious in their imaging behaviour.
- Forums for learning within the wider trauma teams should be created, thereby sharing knowledge of imaging findings and thresholds to image.

### Definition of penetrating trauma

- Penetrating trauma relates to an injury that breaches the skin surface and includes, although is not limited to, stabbings, ballistic injury and foreign body insertion.
- The decision to image the child to assess the extent of any internal injury is primarily a clinical one.

### Definition of blast injury

- Blast injuries are a complex type of physical trauma resulting from direct or indirect exposure to an explosion.
- Blast injuries can involve multiple anatomic regions and be associated with different life-threatening injuries (for example, catastrophic haemorrhage, severe head trauma).
- In a multi-trauma blast incident the risk of injury and death is as high if not higher in children than adults and this should be taken into consideration when prioritising imaging.
- The type and severity of these injuries will vary depending on different factors including the nature of the explosive device (blast or fragmentation weapon), distance from the blast, blast location (enclosed space or outside) and whether the explosion results from an improvised explosive device (IED).<sup>b</sup>
- The recommendations in this guidance are intended to provide a practical approach to the imaging of blast injuries in children, specifically in the context of a major incident and when multiple victims are expected to arrive at the hospital. It combines lessons learned from recent major incidents, including the Manchester Arena attack in May 2017.

# A6

## Background information

## Classification of blast injury

Classification of blast injury helps to further understand its mechanisms and associated injuries:<sup>b</sup>

- **Primary** injuries are the result of direct tissue damage by the blast wave
- **Secondary** injuries derive from fragments of the device or surrounding environment
- **Tertiary** injuries are from body displacement and impact into surfaces such as walls and vehicles
- **Quaternary** injuries are related to burns, inhalation and drowning
- **Quinary** injuries have their major morbidity and mortality several days to weeks after and are the result of late complications of the previous types, such as infections related to shrapnel contaminated with biological fluids or the result of major tissue damage.

## References

- a. Trauma Audit and Research Network (TARN). Severe injury in children, Jan 2019–Dec 2020. [www.researchgate.net/publication/364663436\\_The\\_Trauma\\_Audit\\_and\\_Research\\_Network\\_TARN\\_Severe\\_Injury\\_in\\_Children\\_January\\_2019\\_-\\_December\\_2020](http://www.researchgate.net/publication/364663436_The_Trauma_Audit_and_Research_Network_TARN_Severe_Injury_in_Children_January_2019_-_December_2020) (last accessed September 2024).
- b. NHS England. Clinical guidelines for major incidents and mass casualty events. NHS England, 2018. [www.england.nhs.uk/publication/clinical-guidelines-for-major-incidents-and-mass-casualty-events](http://www.england.nhs.uk/publication/clinical-guidelines-for-major-incidents-and-mass-casualty-events)

## Acknowledgements

We are very grateful to the working group who led on the development of this publication.

**Chair:** Judith Foster, consultant paediatric radiologist, Plymouth

John Adu, consultant paediatric diagnostic and interventional radiologist, London

Annamaria Deganello, consultant paediatric radiologist, London

Sarah Griffin, professional standards project officer, the RCR

Giles Haythornthwaite, consultant in paediatric emergency medicine, Bristol

Karl Johnson, consultant paediatric radiologist, Birmingham

Samantha Low, consultant paediatric radiologist, Birmingham

Manigandan Thyagarajan, consultant paediatric radiologist, Birmingham

Rui Santos, consultant paediatric radiologist, London

The Royal College of Radiologists  
63 Lincoln's Inn Fields  
London, WC2A 3JW, UK



The Royal College of Radiologists  
is a Charity registered with the  
Charity Commission No 211540.

+44 020 7405 1282  
enquiries@rcr.ac.uk  
rcr.ac.uk

📷 ✂ @RCRadiologists



The Royal College of Radiologists

The Royal College of Radiologists. *Major paediatric trauma radiology guidance*. London: The Royal College of Radiologists, 2024.

The Royal College of Radiologists is a Charity registered with the Charity Commission No. 211540

© The Royal College of Radiologists, October 2024.

This material has been produced by The Royal College of Radiologists (RCR) for use internally within the specialties of clinical oncology and clinical radiology in the United Kingdom. It is provided for use by appropriately qualified professionals, and the making of any decision regarding the applicability and suitability of the material in any particular circumstance is subject to the user's professional judgement.

While every reasonable care has been taken to ensure the accuracy of the material, RCR cannot accept any responsibility for any action taken, or not taken, on the basis of it. As publisher, RCR shall not be liable to any person for any loss or damage, which may arise from the use of any of the material. The RCR does not exclude or limit liability for death or personal injury to the extent only that the same arises as a result of the negligence of RCR, its employees, Officers, members and Fellows, or any other person contributing to the formulation of the material.